

Successful Treatment of a Case of COVID-19 Pneumonia Following Kidney Transplantation Using Paxlovid and Tocilizumab

Qian Chen¹, Tao Zhang¹, Sheng Chao¹, Lei Jia¹, Qizhen Yang¹, Yuling Niu^{1*} and Shi Zuo^{2*}

¹Department of Organ Transplantation, Affiliated Hospital of Guizhou Medical University, China

²Department of Hepatobiliary Surgery, Affiliated Hospital of Guizhou Medical University, China

*Corresponding author: Yuling Niu, Department of Organ Transplantation, Affiliated Hospital of Guizhou Medical University, Guiyang, China, E-mail: 304781311@qq.com

Shi Zuo, Department of Hepatobiliary Surgery, Affiliated Hospital of Guizhou Medical University, Guiyang, China, E-mail: drzuoshi@gmc.edu.cn

Abstract

Since its initial detection in 2019, coronavirus disease 2019 (COVID-19) pneumonia has rapidly spread throughout the world in a global pandemic. However, reports of COVID-19 pneumonia among patients following kidney transplantation have been limited and no uniform treatment guidelines for these patients have yet to be established. Here, we report the case of a 39-year-old patient recovering from kidney transplantation who contracted perioperative COVID-19 pneumonia that was successfully controlled with oral Paxlovid and a single intravenous drip infusion of Tocilizumab following the discontinuation of immunosuppressive drugs. Given the rapid spread of SARS-CoV-2 infections, clinicians should be aware of the potential for more cases of COVID-19 among patients following kidney transplantation and be familiar with appropriate treatment options and likely clinical outcomes.

Keywords: Clinical research; Kidney transplantation; COVID-19 pneumonia; Paxlovid; Tocilizumab

Introduction

The COVID-19 (coronavirus disease 2019) pandemic was first detected as an outbreak of pneumonia in the Wuhan region of China in December 2019 [1,2], and the causative SARS-CoV-2 virus has remained highly transmissible [3]. The progression of the pandemic has varied markedly among countries throughout the world, with differences in circulating viral strains and control efforts in different regions. For example, several devastating mutant strains in Italy have rapidly emerged and caused critical illness, particularly among older adults and immunocompromised individuals [4]. Prolonged immunosuppressive treatment is essential among transplant recipients in order to prevent rejection, thus inevitably suppressing the immune status of these

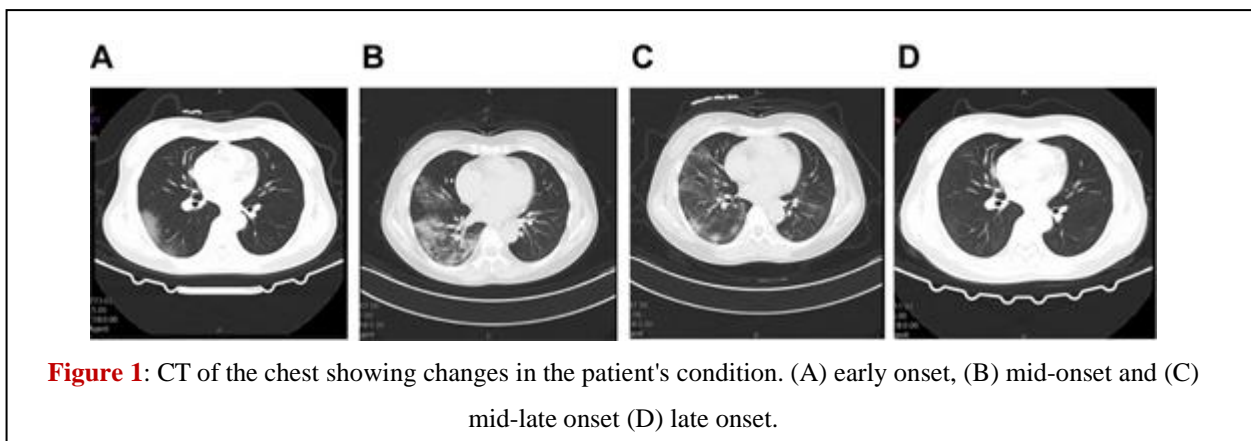
individuals as compared to the general population. At present, there is a lack of reported cases of COVID-19 pneumonia in kidney transplant patients, and there are no uniform treatment standards for these individuals [5]. The efficacy of different treatments, the optimal symptomatic management strategies, and the prognostic outcomes in kidney transplant recipients suffering from COVID-19 are also not well understood [6,7]. Here, we describe the case of a 39-year-old male that contracted and was successfully treated for COVID-19 pneumonia after the completion of a kidney transplant procedure. Given the current challenges associated with controlling and preventing the spread of COVID-19, clinicians performing kidney transplantation should be aware of the risk of perioperative infection. By publishing this case report, we hope to provide a reference for kidney transplant teams seeking to effectively manage post-transplant patient recovery.

Case Presentation

A 39-year-old male was admitted to the Affiliated Hospital of Guizhou Medical University (Guiyang, China) on 19 December 2022 due to a 3-year history of elevated creatinine levels of 2 years or regular hemodialysis. He had expressed interest in receiving a transplanted kidney and was awaiting a suitable donor following a matching test. The patient had been free of any nausea, vomiting, or diarrhea since disease onset, and did not exhibit any masses or positive signs including abdominal pressure, rebound pain, or abdominal muscle tone upon examination. He had a prior history of hypertension with blood pressure levels of up to 180/90 mmHg managed through the long-term use of controlled-release nifedipine tablets. He had no history of diabetes mellitus, hepatitis, or tuberculosis. On admission, his nucleic acid test results indicated that he was negative for COVID-19 pneumonia. On day two following admission, the patient's creatinine was 320 $\mu\text{mol/L}$, his estimated glomerular filtration rate was 25 mL/min, and his hemoglobin level was 108 g/L. On the third day, he underwent allogeneic kidney transplantation under general anesthesia, with rabbit anti-human thymocyte immunoglobulin for immune induction and mescaline sodium + prednisone acetate + tacrolimus for immune maintenance. He was administered an empirical antimicrobial treatment consisting of piperacillin sodium/tazobactam sodium (4.5 g/d). Sputum and urine culture results were negative, and serum Calcitoninogen was negative and interleukin 164 pg/mL. On day 14 of admission, the patient began exhibiting a persistent fever. Given the recent rise in COVID-19 infections in the country, the patient was regarded as possibly being infected with COVID-19 and he was thus placed in an isolated single-occupancy room. A pharyngeal swab was collected for SARS-CoV-2 Reverse Transcription Polymerase Chain Reaction (RT-PCR) testing, which was positive for the presence of this virus. Repeated chest Computed Tomography (CT) scans revealed patchy shadows in both lungs consistent with the possibility of viral pneumonia (Figure 1A). On the day of diagnosis, his arterial pO₂ had fallen to 74 mmHg and continuous oxygenation was initiated via nasal cannula and a face mask. Oral Paxlovid (Nirmatrelvir, 150 mg and Ritonavir, 100 mg, Pfizer) Q12h was administered, while the anti-rejection drugs mescaline sodium and tacrolimus were discontinued. The patient's IL-6 levels were rechecked and had risen to 314 pg/mL. After a discussion with our infectious specialist and obtaining written informed consent from the patient, Tocilizumab was intravenously administered at a dose of 8 mg/kg diluted in 100 mL of 0.9% saline. After 4 days the patient exhibited no improvements in clinical symptoms and chest CT revealed significant worsening relative to the previous scan (Figure 1B). Following further discussion with our team of physicians, we speculated that reductions in leukocyte counts may be related to the activity of Tocilizumab. In an effort to improve the overall immune status of this patient, we administered

5 g/d of intravenous immunoglobulin. It continued to be used for one week. One week following COVID-19 pneumonia, the patient's pO₂ levels gradually rose and were maintained at 90-95% following the discontinuation of Paxlovid and Tocilizumab treatment. When IL-16 levels were measured 5 days after drug administration, they had fallen to 42.42 pg/mL.

On day 7 of the onset, a chest CT showed some degree of absorption relative to previous scans (**Figure 1C**). On day 28 following admission, the patient was discharged. At the time of discharge, he was free of fever or sputum production, exhibited a pO₂ of 96%, a respiratory rate of 16 breaths/min, and a controlled blood pressure of 136/82 mmHg. Repeat chest CT (**Figure 1D**) and pharyngeal swab testing for COVID-19 were negative on day 10 after the confirmed diagnosis. Tacrolimus and prednisone acetate were continued, and the patient was advised to undergo repeat outpatient testing after 1 week.



Discussion

The ongoing COVID-19 pandemic caused by the SARS-CoV-2 virus has caused over 500 million confirmed infections and 8 million deaths throughout 223 countries and territories [8,9]. The highest number of confirmed cases to date has been reported in the USA. Specific treatment options are lacking, with only symptomatic and routine care for infected individuals. Emerging mutant strains of SARS-CoV-2 represent a particularly substantial threat to post-transplant patients, as these individuals often need to attend outpatient check-up appointments and are more often hospitalized due to their immunosuppressed status [10,11]. These unique population characteristics can place these individuals at a high risk of severe illness or death. The incubation period for COVID-19 infections reportedly varies from 1-24 days [12]. The initial presenting symptoms in infected patients are relatively nonspecific and can include fever and an upper respiratory tract infection [13]. These signs and symptoms also vary among patients, and the early detection and management of COVID-19 infections is thus vital to improving therapeutic outcomes and reducing the odds that patients develop severe disease [14,15]. After undergoing organ transplantation, patients face a persistent risk of severe illness and death upon COVID-19 infection owing to their impaired immune function [16]. Most kidney transplant patients have also not been vaccinated against COVID-19, and those that have generally exhibit relatively weak vaccine-induced humoral immunity such that they face very high rates of morbidity and mortality [17]. When they do contract COVID-19, these patients are more likely to progress to severe disease such that they are a particularly important group to provide with therapeutic interventions when possible. However, the precise efficacy of

different interventional regimens in COVID-19 patients that are also transplant recipients is likely to vary as the virus continues to mutate.

In the present case, when our patient was diagnosed with COVID-19 pneumonia we initially elected to discontinue immunosuppressive treatment with tacrolimus and mycophenolate while maintaining low-dose steroid treatment in light of the high risk of simultaneous bacterial infection [18]. Paxlovid is a recently developed COVID-19 treatment developed by Pfizer that consists of a combination of Nirmatrelvir and Ritonavir, a peptidomimetic analog of Mpro (3C-like protease) that serves as the primary protease used by SARS-CoV-2 [19]. Ritonavir can inhibit the metabolic processing of Nirmatrelvir by cytochrome P4503A (CYP3A), thus increasing the circulating levels of this drug. Paxlovid received emergency use authorization from the US Food and Drug Administration (FDA) as a treatment for mild-to-moderate COVID-19 in light of its favorable efficacy. Several studies have confirmed that Paxlovid administration within the first 5 days after SARS-CoV-2 infection can expedite viral clearance [20]. However, some researchers have questioned the methodology employed in these studies and have suggested that the results are exaggerated. Even so, given the lack of more effective treatment options, Paxlovid represents a promising candidate treatment for patients recovering from kidney transplantation who are infected with COVID-19. Accordingly, we elected to use Paxlovid to treat our patient following confirmed SARS-CoV-2 infection, with a total Paxlovid treatment course lasting 5 days. Some reports have indicated that infection with SARS-CoV-2 can result in severe lung damage as a consequence of cytokine release syndrome mediated by an overzealous host immune response to the virus. Those patients with severe disease tend to exhibit higher levels of IL-6 as compared to patients with less severe disease. Tocilizumab is initially used to treat adult patients with moderately severe active rheumatoid arthritis that have failed to satisfactorily respond to disease-modifying anti-rheumatic drug treatment [21]. Some COVID-19 patients will experience severe disease characterized by dyspnea, respiratory failure, and acute respiratory distress syndrome driven by IL-6 and other components of cytokine release syndrome in critical cases. The use of the IL-6 receptor antagonist Tocilizumab as a treatment for severely ill COVID-19 patients thus has the potential to mitigate these severe outcomes [22]. In this case, we treated our patient with Tocilizumab given his high circulating IL-6 concentrations in an effort to protect against further lung lesions and associated pulmonary distress. At present, there is no consensus regarding the optimal timing of Tocilizumab administration when treating COVID-19, and given that our patient experienced positive clinical outcomes with a single dose of Tocilizumab, we did not administer any further doses. It is important to note that IL-6 levels may remain temporarily elevated following the initiation of Tocilizumab treatment as the antibody blocks the IL-6 receptor, whereas the ligand itself remains in circulation and degrades over time. In the present case, the patient was also administered immunoglobulin to enhance his immune system.

In summary, we have herein detailed a case of COVID-19 pneumonia that developed during the perioperative period in a patient that underwent kidney transplantation to treat end-stage kidney disease. The patient was successfully treated with a series of drugs including Paxlovid, Tocilizumab, and human immunoglobulin together with the temporary discontinuation of the immunosuppressive therapy given following transplantation. While informative, this case is subject to several limitations. As this is a single case, it is not sufficient to formulate treatment guidelines for these multiple, and the self-healing process in COVID-19 patients following kidney transplantation remains to be fully elucidated. Even so, we believe that this case will provide a valuable reference to clinicians in transplant units, aiding in the recognition and potential treatment of

COVID-19 pneumonia among individuals in the perioperative period following transplantation. Given the sustained high rates of COVID-19 infections throughout the globe, we believe that descriptions of the effective management of exceptional cases are important as a focus of concern for transplant surgeons until sufficiently large volumes of data are available from clinical studies to provide more robust guidance.

Funding

This research was supported by Guiyang Science and Technology Program (2019-9-1-39).

References

1. [WJ Guan, NS Zhong. Clinical Characteristics of Covid-19 in China. N Engl J Med. 2020;382\(18\):1708-20.](#)
2. [ZY Zu, Jiang PP, Xu W, Chen QQ, Ni GM, Lu LJ, et al. Coronavirus Disease 2019 \(COVID-19\): A Perspective from China. Radiology. 2020;296\(2\):E15-E25.](#)
3. [P Mo, Y Xing, Y Xiao, L Deng, Q Zhao, H Wang, et al. Clinical Characteristics of Refractory Coronavirus Disease 2019 in Wuhan, China. Clin Infect Dis. 2021;73\(11\):e4208-e4213.](#)
4. [G Onder, G Rezza, S Brusaferro. Case-Fatality Rate and Characteristics of Patients Dying in Relation to COVID-19 in Italy. JAMA. 2020;323\(18\):1775-76.](#)
5. [J Hippisley-Cox, CA Coupland, N Mehta, RH Keogh, K Diaz-Ordaz, K Khunti, et al. Risk prediction of covid-19 related death and hospital admission in adults after covid-19 vaccination: national prospective cohort study. BMJ. 2021;374:n2244.](#)
6. [Desai JF, Gainor A, Hegde AM, Schram G, Curigliano S, Pal SV, et al. COVID-19 vaccine guidance for patients with cancer participating in oncology clinical trials. Nat Rev Clin Oncol. 2021;18\(5\):313-9.](#)
7. [V Mahalingasivam, G Su, M Iwagami, MR Davids, JB Wetmore, D Nitsch. COVID-19 and kidney disease: insights from epidemiology to inform clinical practice. Nat Rev Nephrol. 2022;18\(8\):485-98.](#)
8. [SH Safiabadi Tali, JJ LeBlanc, Z Sadiq, OD Oyewunmi, C Camargo, B Nikpour, et al. Tools and Techniques for Severe Acute Respiratory Syndrome Coronavirus 2 \(SARS-CoV-2\)/COVID-19 Detection. Clin Microbiol Rev. 2021;34\(3\):e00228-20.](#)
9. [M Yüce, E Filiztekin, KG Özkaya. COVID-19 diagnosis -A review of current methods. Biosens Bioelectron. 2020;165:112349.](#)
10. [Q Fernandes, VP Inchakalody, M Merhi, S Mestiri, N Taib, D Moustafa Abo El-Ella, et al. Emerging COVID-19 variants and their impact on SARS-CoV-2 diagnosis, therapeutics and vaccines. Ann Med. 2022;54\(1\):524-40.](#)
11. [Y Azzi, M Parides, O Alani, P Loarte-Campos, R Bartash, S Forest, et al. COVID-19 infection in kidney transplant recipients at the epicenter of pandemics. Kidney Int. 2020;98\(6\):1559-67.](#)
12. [P Cravedi, SS Mothi, Y Azzi, M Haverly, SS Farouk, MJ Pérez-Sáez, et al. COVID-19 and kidney transplantation: Results from the TANGO International Transplant Consortium. Am J Transplant. 2020;20\(11\):3140-8.](#)
13. [V Nair, N Jandovitz, JS Hirsch, G Nair, M Abate, M Bhaskaran, et al. COVID-19 in kidney transplant recipients. Am J Transplant. 2020;20\(7\):1819-25.](#)
14. [C Radcliffe, CF Palacios, MM Azar, E Cohen, M Malinis. Real-world experience with available,](#)

- [outpatient COVID-19 therapies in solid organ transplant recipients during the omicron surge. Am J Transplant. 2022;22\(10\):2458-63.](#)
15. [E Goffin, A Candellier, P Vart, M Noordzij, M Arnol, A Covic, et al. Gansevoort, COVID-19-related mortality in kidney transplant and haemodialysis patients: a comparative, prospective registry-based study. Nephrol Dial Transplant. 2021;36\(11\):2094-105.](#)
 16. [BG Abu Jawdeh. COVID-19 in Kidney Transplantation: Outcomes, Immunosuppression Management, and Operational Challenges. Adv Chronic Kidney Dis. 2020;27\(5\):383-9.](#)
 17. [M Karatas, E Tatar, C Simsek, AM Yildirim, A Ari, B Zengel, et al. COVID-19 pneumonia in kidney transplant recipients: A promising treatment algorithm in the absence of a disease-specific drug. J Med Virol. 2021;93\(10\):5789-97.](#)
 18. [K El Karoui, AS De Vriese. COVID-19 in dialysis: clinical impact, immune response, prevention, and treatment. Kidney Int. 2022;101\(5\):883-94.](#)
 19. [R Najjar-Debbiny, N Gronich, G Weber, J Khoury, M Amar, N Stein, et al. Effectiveness of Paxlovid in Reducing Severe COVID-19 and Mortality in High Risk Patients. Clin Infect Dis. 2022;ciac443.](#)
 20. [RECOVERY Collaborative Group: Peter W Horby, Marion Mafham, Jennifer L Bell, Louise Linsell, Natalie Staplin, Jonathan Emberson, et al. Lopinavir-ritonavir in patients admitted to hospital with COVID-19 \(RECOVERY\): a randomised, controlled, open-label, platform trial. Lancet. 2020;396\(10259\):1345-52.](#)
 21. [IO Rosas, G Diaz, RL Gottlieb, SM Lobo, P Robinson, BD Hunter, et al. Tocilizumab and remdesivir in hospitalized patients with severe COVID-19 pneumonia: a randomized clinical trial. Intensive Care Med. 2021;47\(11\):1258-70.](#)
 22. [EC Somers, GA Eschenauer, JP Troost, JL Golob, TN Gandhi, L Wang, et al. Tocilizumab for Treatment of Mechanically Ventilated Patients With COVID-19. Clin Infect Dis. 2021;73\(2\):e445-e454.](#)

Citation of this Article

Chen Q, Zhang T, Chao S, Jia L, Yang Qz, Niu YL and Zuo S. Successful Treatment of a Case of COVID-19 Pneumonia Following Kidney Transplantation Using Paxlovid and Tocilizumab. *Mega J Case Rep.* 2023; 6: 2001-2006.

Copyright

© 2023 Niu YL and Zuo S. This is an open-access article distributed under the terms of the [Creative Commons Attribution License \(CC BY\)](#). The use, distribution or reproduction in other forums is permitted, provided the original author(s) or licensor are credited and that the original publication in this journal is cited, in accordance with accepted academic practice. No use, distribution or reproduction is permitted which does not comply with these terms.